

CHARLES UNIVERSITY IN PRAGUE,  
FACULTY OF PHYSICAL EDUCATION AND SPORT,  
DEPARTMENT OF ANATOMY AND BIOMECHANICS

## **SHAPE MANIFESTATION OF RESPIRATION IN THE AXIAL SYSTEM**

ELIŠKA SLAWIKOVÁ, MONIKA ŠORFOVÁ & TEREZA DOLANSKÁ

### SUMMARY

The aim of the study was to evaluate the effect of respiration on the shape changes of the axial system. Our approach focuses more on the analysis of respiratory function and their implementation within the complex axial system – the trunk. The results of this pilot study will use as evidence for further study of relationship between respiration and physiotherapy. Now we are looking for an answer to the question, at what level of the human body reflected the influence of respiration and its use in physiotherapy.

This pilot study was attended by two women and one man aged 25–40 years, who were not selected for the study according to predetermined conditions. The same characteristic features of all three participants were sedentary job connected with excessive mental strain, occasional low back pain (usually after a long sitting) and the absence of acute or chronic respiratory diseases. Another common feature of the participants was the absence of structural changes in the spine. During the experiment was monitored maximum inhalation and maximum exhalation, and respiratory maneuver Kapalabhati, often used as one of the basic yoga breathing exercises. To detect trunk movement during the respiratory maneuver, we opted for a Qualysis – 3D torso topography. At the same time spirometer panned changes in volume over time, both exhaled and inhaled air.

The purpose of this study was to assess symptoms and implementation of respiratory maneuvers in the axial system, particularly the chest and abdominal area. During the experiment, we followed the differences in reaction of the chest and abdomen in respiratory maneuver in the direction vertical, antero-posterior and lateral. The difference in these indicators at different phases of the respiratory maneuver confirms our assumption of the possibility of influencing the selected folders axial system through appropriately selected respiratory maneuver. After processing of the measurement results, we found a significant superiority of the realized movement in the abdomen compared to the chest region, although this is more a 3D movement, which is given by the kinematic motion of the ribs to the sides. Movement is therefore spatially complex. Spirometric evaluation of the identified volumes is consistent with the measured changes in the shape of the trunk. Overall, it is not necessary to evaluate the results statistically, but case reviews – compare always “formula” realization of the respiratory maneuver that person.

**Keywords:** diaphragm, posture, body shape, mobility of the spine, breathing dynamics, 3D motion analysis, spirometer

## INTRODUCTION

The shape of chest skeleton together with construction and connection of bones forms structural conditions for the realization of respiratory movements. Thoracic spine movements affect the dynamics of breathing; respiration affects spine dynamics. For physiological resting breathing is critical complex chest wall muscles, diaphragm and abdominal wall (Dylevský, 2009).

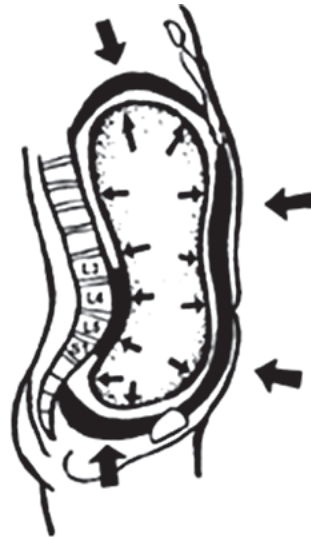
Movement of the ribs and costovertebral and costotransverzal articulation and elevation of the ribs caused by increasing the transverse diameter of the lower part of the chest and anteroposterior diameter upper chest already described Kapandji (1974).

Many research studies have focused on kinesiology point of view, which is a coordination of muscle activity in respiration. The diaphragm itself by its function can magnify all three diameters chest (frontal, sagittal, transverse), and therefore is itself able to perform all the basic functions on the inhale (Véle, 1997). Despite some dominant diaphragm is just one part of a functional complex inspiratory trunk muscles, containing also abdominal muscles and pelvic muscles (Dylevský, 2009). The respiratory muscles are used during inspiration. The inspiration performing work of breathing, which has three components: the work necessary to overcome lung retraction forces, overcoming the resistance of lung tissue and overcome current resistance which put respiratory failure. (Trojan, 2003; Navratil & Rosina, 2005; Slavíková, 2002).

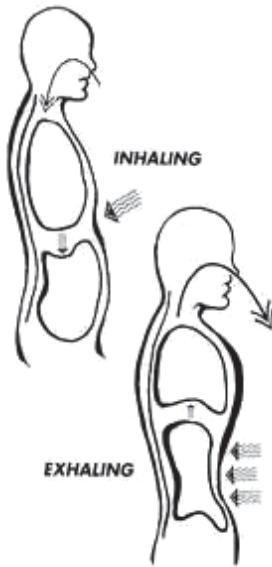
Abdominal muscles can be described as expiratory muscles, which operates mainly in the active expiration (the resistance in the airways) by displacing abdominal organs into the diaphragmatic dome and piston mechanism expel air from the lungs. Most apply mm. obliqui abdominis and m. transversus abdominis (Dylevský, 2009).

Kapalabhati, breathing exercises used in the experiment is based on active exhalation, which is fast and sharp, and conversely passive, slow breath. Kapalabhati consists of short doses sharply exhaled air, followed by passive inhale (Lysebeth, 1999; Dostalek, 1996).

Kapalabhati begins a sharp, forceful exhalation, downloading abdominal muscles. The air pushes loudly blowing by nose. The mouth is closed all the time. After exhalation breath is not holding, releasing



**Figure 1.** Muscle interaction between autochthonous muscles, diaphragm, muscles of the pelvic floor and abdominal muscles in physiological situation (taken from Kolar & Lewit, 2005)



**Figure 2.** Kapalabhati  
(taken from [www.take-root.com](http://www.take-root.com))

It starts with 12 to 15 breaths, then the number is 60, the maximum is 120 active breaths per minute (Hajek et al., 2000). Exhalation takes about two tenths of a second, breath varies from eight to three tenths of a second to the rhythm in which the exercise is performed (Lysebeth, 1999).

## METHODS

### Qualysis

The system is Qualysis optoelectronic system for 3D motion analysis. The main task is the creation and subsequent kinematic analysis of motion of the object. It uses the camera's own high-precision tracking of the object using passive or active markers.

Labeled markers and evaluated parameters are chosen to define the behavior of individual breathing phases, their location and time sequence. We can concentrate on symmetry made movements, their implementation in the chest, abdomen or overall impact on the shape of the spine, etc.

To assess the implementation of the breath in the thoracic and abdominal parts of the axial system we started the reconstruction of the horizontal trunk transverse section of vertebrae Th9 for the realization of the breath in the chest, and for assessing the functional involvement of abdominal incision of vertebra L3. As the basis of realized breath movements was chosen pelvis, represented by the front and back pelvic spins in both sides.

The results are for better predictive value the parameters such as the anterior-posterior dimension, the lateral width of the selected section in percent (100% represents the size

the abdominal muscles, the air is automatically sucked into the lower and middle parts of the lungs (Kogler, 1971).

Kapalabhati is purely diaphragm type breathing, chest has an important role in that it remains completely immobile. Before training the chest off, and should stay in position of the inhale with ribs splayed. During the exercise can be seen a movement of the lower ribs. The movement is passive and unavoidable hence it is induced by pulling the abdominal wall muscles, associated with these ribs.

The diaphragm is very intensely involved here, but passively. The main movements creates abdominal wall, which compresses the internal organs back and up so the diaphragm is activated – the internal organs through activation of the abdominal wall. The diaphragm is active, but muscles don't contract (Lysebeth, 1999).

of the monitored person in maximum inspiration). Furthermore are evaluated the relative positions of selected slices – in three dimensions, in particular vertical offset.

In the pictures are shown the parameters evaluated marker of left pelvic spines (SIAS) and the marked point at the height of the front left Th9 vertebra to the rib cage. Monitored was the mutual vertical distance of the axis Z (see Figure 3) and sagittal move of the cut at axis Y (see Figure 4).

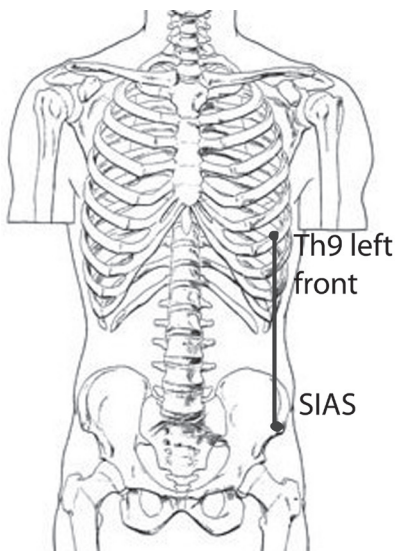


Figure 3. Vertical shift Th9 – SIAS

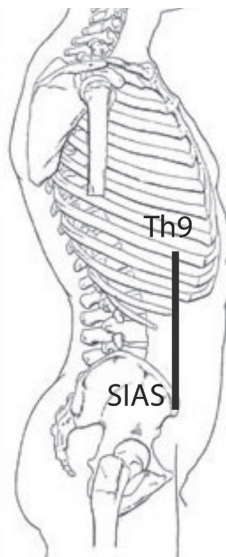


Figure 4. Sagittal shift Th9 – SIAS

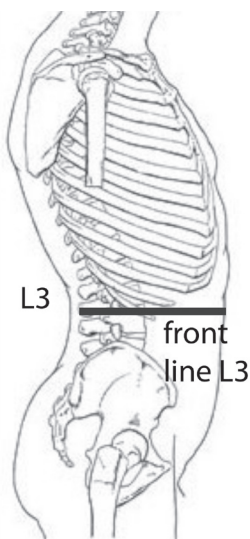
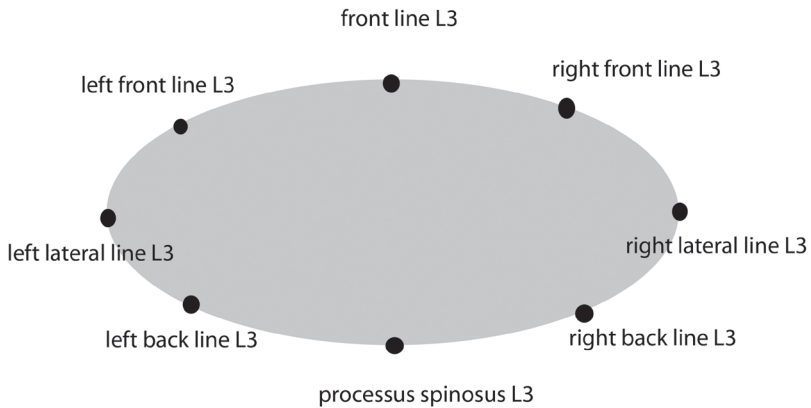


Figure 5. Sagittal shift L3


Similarly, the situation has been evaluated in the abdomen, in the text are displayed parameter evaluated within a reconstructed slice.

At the same time we have to assess respiratory function used spirometric measurements. This on-line measurement allows us to bind each other topographic parameters describe breathing movements with the current volumes change, including the dynamic parameters. Of course it is possible to compute standard rated parameters observable for the respiratory maneuver with standard spirometry.

Monitored parameters were still breathing, maximum inhale and exhale, short and strenuous exhales (Kapalabhati).



**Figure 6.** Diagram of reconstructed slice

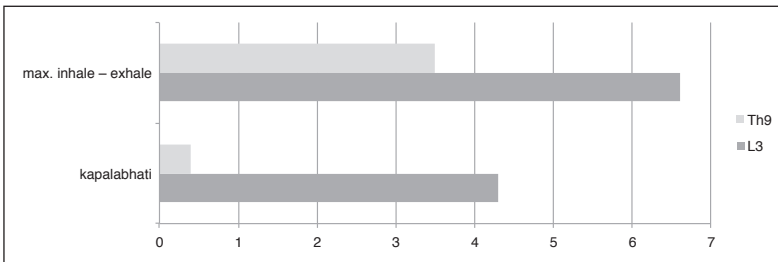


**Figure 7.** Spirometer

## RESULTS

Changes of transverse dimension of the trunk in the sagittal direction changes over the maximum inhale and exhale a maximum of 9%. There is significantly bigger movement in the area of the abdomen (slice L3), where the average value is 6.6%. In contrast, in the region of chest (slice Th9) there are similar displacements in case of the maximum breathing for about 3.5% – or about half value of changes in the abdominal area. From the analyzed breath cycles, we can hypothesize that the shape changes in the antero-posterior direction within one tidal cycle is always bigger in the abdomen than the chest.

In the case of Khapalabhati we have found this phenomenon even more pronounced. The higher value of changes of transverse dimensions seen in the direction of antero-posterior in the region of the abdomen (4.3%) compared to the values of the chest region (0.4%), where it is not carried out almost no movement.



**Figure 8.** Anteroposterior dimension cut L3 (red) and Th9 (blue) at a chosen breath maneuver


Variability of measured values for each person is listed in the following table. Basic trends are repeated, deflections in the abdominal area are at all three participants more significant than in the chest.

**Table 1.** Percentage of the measured values of each proband

| antero-posterior direction | max inhale–exhale | kapalabhati |
|----------------------------|-------------------|-------------|
| proband 1 – Th9            | 4.5               | 0.8         |
| proband 1 – L3             | 9.1               | 5.9         |
| proband 2 – Th9            | 1.2               | 0.3         |
| proband 2 – L3             | 3.6               | 2.1         |
| proband 3 – Th9            | 4.8               | 0.2         |
| proband 3 – L3             | 6.9               | 4.8         |

The movement in the lateral direction was significantly smaller than in the antero-posterior direction. Minimum cross-sectional area change in the lateral direction, we've detected primarily in the region of the abdomen even if the case of maximal inhale and exhale.

Values fall within the measurement errors (about 2 mm). Measurable values shall extend of chest laterally only at maximum inhale and exhale.



**Figure 9.** Display horizontal slice of the thorax vertebrae Th9 Position in breath (blue) and expiration (red)

Measured value of the shift point on the front of the chest of Th9 vertebra to the anterior pelvic spines are averaged 14.6% in the vertical direction and about 4.6% (higher variability of results) in the anteroposterior direction. It's always a movement within one tidal cycle and 100% is the vertical distance at maximum inspiration. Values therefore describe the spatial movement chosen cut during tidal cycle.

The evaluation of the breathing volumes is in accordance with the measured changes in the shape of the trunk. The average value of the volume during maximal respiration is 3.2 liters. Its variability – repeated for four times – was up to 40%. In case of Kapalabhati, the breathing volume was reduced to approximately 0.7 liter only (i.e. to about 22% of the maximum breathing volumes of reference person).

Variability of breathing cycles is not possible any indication of a functional state. It is a process driven CNS and carried out a number of subsystems, the consistency of the by no means required.

## DISCUSSION

The task of this study was to perform an experiment using 3D motion analysis Qualisys, supplemented of spirometry measurement. Both of these measurements were evaluated separately, because the time of spirometry measurements don't agree the time interval of Qualisys, data is not synchronized.

Qualisys system provides data from which it is possible to evaluate a large number of parameters, the mutual distance markers and dependence on time. Within the scope of this study, the parameters were chosen few. Mainly those in which markers were well captured by cameras and data could thus be complete. It was interesting to watch the individual response the chest and abdomen on respiratory maneuvers Kapalabhati and deep breathing. The results confirm and tell us about individual response all probands to individual maneuver.

Qualisys can help diagnose the musculoskeletal system at the level of structural or functional disorders. For example, scoliosis curvature of the spine or formation of muscle

imbalances in the upper trunk and changes related to breathing stereotype. It is likely that in the long term application of respiratory maneuvers, such as every day, the result would be more visible, which could be the subject of further research.

The results of spirometry or Qualysis are not significant. They cannot be compared with each other because only one measurement was carried out. By this time, no published studies, neither the Czech Republic nor in the world, dealing with the influence of Kapalabhati the trunk shape changes and changes in lung volumes. Kapalabhati already been the subject of several studies, mostly from the Indian experts dealing with the impact Kapalabhati of the alveolar concentration of carbon dioxide (Kupalayanand & Karambelkar, 1958) levels of urea, creatinine and tyrosine (Desai & Gharote, 1990), Stančák, Kuna, Srinivasan and Dostálek (1991) found out the changes in the EEG. These and many other studies are focused on change and affecting the function of the internal organs of the abdominal cavity and chest. The reason more internal focus of these studies can be an influence on the digestive tract, pelvic organs and the heart through activation of the diaphragm and abdominal muscles and thus changes in intra-thoracic and intra-abdominal pressure.

In further work, we want to focus on the analysis of the maximal respiration and its detection in the case of urgent axial system difficulties. We want to focus to analysis of respiration movements persons with permanent deformity of the body (for example scoliosis). As a result of restrictions of shape and function in the region of axial system we expect different spirometry parameters and their dynamics and also a different implementation in the framework of cooperation-chest-abdomen – pelvis – diaphragm.

## ACKNOWLEDGEMENTS

This project is supported by GA CR P 407/10/1624, PRVOUK 38.

## REFERENCES

- DESAI, B. P. & GHAROTE, M. L. (1990). Effect of Kapalabhati on blood urea, creatinine and tyrosine. *Activitas Nervosa Superior*, 32(2), pp. 95–98.
- DOSTÁLEK, C. (1996). *Hathajóga*. Praha: Karolinum.
- DYLEVSKÝ, I. (2009). *Funkční anatomie*. 1st ed. Praha: Grada.
- KAPANDJI, I. A. (2004). *The physiology of the joints*. 20th ed. London: Churchill Livingstone.
- KOGLER, A. (1971). *Jóga – základy tělesných cvičení*. Bratislava: Slovenské tělovýchovné nakladatelstvo.
- KOLÁŘ, P. & LEWIT, K. (2005). Význam hlubokého stabilizačního systému v rámci vertebrogenních obtíží. *Neurologie pro praxi*, 5, pp. 270–275.
- KUVALAYANANDA, S. & KARAMBELKAR, P. V. (1958). Studies in alveolar air in Kapalabhati. *Yoga mimansa*, 7, pp. 18–25.
- LYSEBETH, A. (1999). *Pránajána: Technika dechu*. 1st ed. Praha: Argo.
- NAVRÁTIL, L. & ROSINA, J. (2005). *Medicínská biofyzika*. Praha: Grada.
- STANČÁK, A., KUNA, M., SRINIVASAN, DOSTÁLEK, C. & VISHNUDEVANANDA, S. (1991). Kapalabhati – yogic cleansing exercise, EEG topography analysis. *Homeostasis in health and disease international journal devoted to integrative brain functions and homeostatic systems*, 33(4), pp. 182–189.
- TROJAN, S. (2003). *Lékařská fyziologie*. 4th ed. Praha: Grada.
- VÉLE, F. (1997). *Kineziologie pro klinickou praxi*. Praha: Grada.



## TVAROVÉ PROJEVY RESPIRACE V RÁMCI AXIÁLNÍHO SYSTÉMU

ELIŠKA SLAWIKOVÁ, MONIKA ŠORFOVÁ & TEREZA DOLANSKÁ

SOUHRN

Cílem práce bylo zhodnotit vliv respirace na tvarové změny axiálního systému. Náš přístup se zaměřuje podrobněji na analýzu dechových funkcí a jejich realizaci v rámci komplexu axiální systém – trup. Výsledky této pilotní studie využijeme jako poznatky pro další studium vztahu respirace a fyzioterapie. Nyní hledáme odpověď na otázku, na jaké úrovni lidského těla se odrazí vliv respirace a její využití ve fyzioterapii.

Této pilotní studie se zúčastnili dvě ženy a jeden muž ve věku 25–40 let, kteří nebyli vybráni do studie podle předem daných podmínek. Shodnými charakteristickými rysy všech 3 probandů bylo sedavé zaměstnání spojené s nadměrnou psychickou zátěží, občasnou bolestí bederní páteře (nejčastěji po dlouhodobém sezení) a absence akutního či chronického onemocnění dýchacích cest. Dalším společným prvkem účastníků byla absence strukturálních změn v oblasti páteře. V experimentu byl sledován maximální nádech a maximální výdech a také respirační manévry Kapalabhati, často používaný jako jeden ze základních jógových dechových cvičení. Pro detekci pohybu trupu během respiračního manévru jsme zvolily popis 3D topografie trupu metodou Qualisys. Zároveň byla spirometrem snímána změna objemů v čase, a to jak vydechovaného, tak nadechovaného vzduchu. Smyslem této studie bylo posoudit projevy a realizaci respiračních manévru na axiální systém, především hrudní a abdominální oblast. Během experimentu byly sledovány rozdíly v reakci hrudníku a břicha při respiračním manévru ve směru vertikálním, předozadním a laterálním. Rozdílnost v těchto ukazatelích při jednotlivých fázích respiračního manévru nám potvrzuje předpoklad možnosti ovlivnění vybraných složek axiálního systému prostřednictvím vhodně zvoleného respiračního manévru. Po zpracování výsledků měření byla zjištěna výrazná převaha realizovaného pohybu v oblasti břicha oproti regionu hrudníku, i když zde má pohyb více charakter 3D, který je dán kinematickým pohybem žebor do stran. Pohyb je tedy prostorově komplexnější. Spirometrické vyhodnocení zjištěných objemů je v souladu s naměřenými změnami tvaru trupu. Celkově je nutné hodnotit výsledky ne statisticky, ale kazuisticky – porovnávat vždy „vzorec“ realizace daného dechového manévru danou osobou.

**Klíčová slova:** bránice, postura, tvar trupu, pohyblivost páteře, dynamika dýchání, 3D analýza pohybu, spirometr

Eliška Slawiková  
slawikova.e@gmail.com

Monika Šorfová  
sorfova@seznam.cz

Tereza Dolanská  
dolanskat@gmail.com